

Brachytherapy Boost in the Neoadjuvant Radiation Therapy for Locally Advanced Rectal Cancer at King Abdulaziz University Hospital

Yasir A. Bahadur, MBBS, FRCRC

*Department of Radiology, Faculty of Medicine,
King Abdulaziz University, Jeddah, Saudi Arabia
yasirbahadur@hotmail.com*

Abstract. The aim is to evaluate the pathological complete response and toxicity when using brachytherapy boost as part of the preoperative chemoradiation therapy in patients with rectal cancer. A retrospective review of all patients with rectal cancer treated at King Abdulaziz University Hospital. Fifty-five patients had neoadjuvant radiotherapy 45 Gy in 25 fractions of external beam radiation as Phase I of radiotherapy followed by external beam boost: 540 cGy/3 fractions in 31 patients or Ir192 HDR brachytherapy boost in 17 patients. The pathological response rate, toxicity profile, overall survival and disease free survival was compared between different radiation therapies modalities. The pathological response rate was complete in 14 (25.5%) patients, partial (PR) in 29 (52.7%) patients, unknown (did not do surgery) in 9 (16.5%) patients and stable disease in 3 (5.4%) patients. In brachytherapy boost, pathological complete response was 47% vs. 18% external beam boost ($p = 0.004$). Toxicity profile was better in the brachytherapy group. Overall survival was 93% and the disease free survival was 60% which were not influenced by the modality of radiation therapy used. High Dose Rate Brachytherapy boost result in a higher pathological response rate without increase in side effect as compared to the external beam radiation boost in the neoadjuvant radiation therapy for locally advanced rectal cancer.

Keywords: High dose rate brachytherapy, Rectal cancer.

Introduction

In the United States, approximately 41,420 patients are diagnosed with rectal cancer every year^[1]. However, The Saudi National Cancer

Correspondence & reprint request to:

Dr. Yasir A. Bahadur
P.O. Box 80215, Jeddah 21589, Saudi Arabia

Accepted for publication: 25 March 2009. Received: 15 December 2008.

Registry showed that colorectal cancer is the third most common type of cancer diagnosed in the year 2004 representing 7.8% of all new diagnosed cancers^[2].

Management of distal rectal cancer poses major challenges in terms of local tumor control and preservation of the anal sphincter. Abdominoperineal resection (APR) has long been considered to be the standard operation for lower rectal tumors with a distal edge less than 6 cm from the anal verge. However, despite providing excellent local control and survival, the APR entails a permanent colostomy as well as high incidence of sexual and urinary dysfunctions. For patients with larger or more invasive tumors, preoperative (neoadjuvant) radiation therapy and chemo radiotherapy have been utilized to promote tumor regression in an attempt to convert a planned APR to a sphincter-sparing surgical procedure^[3-5]. The incidence of sphincter preservation in neoadjuvant chemoradiation therapy in rectal cancer ranges from 39% to 94% (average 67%^[6-14]). The aim of the current study is to assess the efficacy of High Dose Rate Brachytherapy (HDRB) boost as part of neoadjuvant radiation therapy concomitant with chemotherapy in terms of pathological response rate, disease free and overall survival.

Patients and Methods

The study had been conducted in Radiation Oncology Department at King Abdulaziz University Hospital in Jeddah, Saudi Arabia. This study is a retrospective review of patients with rectal cancer referred for neoadjuvant chemo radiation therapy before a definitive surgery had been evaluated. This study includes all patients with pathologically proven rectal carcinoma; locally advanced (T3, or T4) lesions, with no evidence of distant metastases as proved by CT scan chest abdomen, plus pelvis and bone scan before initiation of treatment. Patients must be able to sign an informed consent. Clinical tumor (T) and lymph node (N) stages were identified by pelvic MRI or trans-rectal ultrasound. Baseline hematological, renal and electrolyte profiles should be within normal range to start on chemotherapy.

All patients received neoadjuvant chemotherapy; comprised of 5-FU bolus (325 mg/m² daily) with leucovorin (20 mg/m² daily), both given for five days a week; 1 and 5 of radiation therapy.

CT planning for all patients was done in the treatment position (prone) for Phase I (whole pelvis) and Phase II (boost field to rectum); planning system (Eclipse) were used. Radiation therapy was given as whole pelvic irradiation (Phase I) 45 Gy / 25 fractions / 5 weeks given as daily treatments, for 5 days per week and two days rest; each radiation fraction dose was 180 cGy using linear accelerator with 3 fields; one direct posterior and two lateral fields. The energy used was 6 MV for the posterior field and 18 MV for the lateral fields. Patients were treated in prone position with full bladder as to reduce small bowel toxicity. After Phase I; patients received either the standard external beam radiation boost (540 cGy / 3 fractions / 3 days) using the same field arrangement and energy as for Phase I; with the reduced field size to include the rectum with limited margin. Otherwise, they received brachytherapy using iridium 192 HDR remote after loading source as rectal cylinder applicator, given as an outpatient procedure, once per week for 2 fractions (each is 400 cGy) for a total of 800 cGy prescribed at 0.5 cm; from the applicator surface taking care to block the uninvolved areas with lead blocks mounted in the applicator cylinder.

Acute reactions from the radiation therapy were recorded according to the Radiation Therapy Oncology Group (RTOG) toxicity criteria^[15]. Patients were referred for definitive surgery 4 weeks after the completion of neoadjuvant chemo radiation therapy. Histopathological assessment of response to neoadjuvant radiation and chemotherapy was done according to complete clearance of tumor cells from resection specimen (complete response (CR)); the presence of residual tumor cells in resection specimen (partial response (PR)) or no change from the pre treatment state^[16].

Follow-up after surgery was done as a clinical evaluation (both general physical assessment and rectal examination) every 3 months for the first 2 years, then every 6 months for the 3rd to 5th year, then yearly. Proctosigmoidoscopy was done in yearly basis, however, if local symptoms happened (*i.e.*, progressive constipation or bleeding) an immediate proctosigmoidoscopy would be done. Radiological evaluation (CT scan: chest, abdomen and pelvis; and bone scan) were requested if patient got symptomatic. Disease free survival (DFS) was assessed from the date of diagnosis till the date of relapse (either local or systemic or both) and overall survival (OS) was assessed from the date of diagnosis till the date of the last follow-up. Statistical analysis was done using

SPSS software, and descriptive statistics were used for patients' criteria evaluation. Kaplan and Meier statistics were also used to assess DFS and OS. The prognostic significance of different variables in the study was assessed regarding its influence on DFS or OS using Cox Regression method.

Results

Fifty-five patients have been evaluated during the period of January 2002 till September 2007. Their ages ranged from 29-80 years (mean 53.4 ± 12.2 SD). The clinical and pathological features of patients involved in the study are shown in Table 1.

Table 1. Clinical and pathological features of patients in the study.

Feature	Number	Percentage (%)
Sex:		
Male	36	65.5
Female	19	34.5
Histopathological Grade:	z9	
G1	9	16.4
G2	40	72.7
G3	4	7.3
Unknown*	2	3.6
Tumor (T) Stage :		
T3	37	67.3
T4	10	18.2
Unknown†	8	14.5
Lymph node (N) Stage :		
N0	33	60
N1	12	21.8
N2	2	3.6
Nx‡	8	14.6
Distance from the anal verge :		
Less than 5 cm	35	64
More than 5 cm	20	36

*G Unknown: tumor grade could not be identified

†T Unknown: CT scan only (No MRI / Trans rectal ultra sound)

‡Nx: LN status could not be verified by baseline MRI

Thirty-one (56%) patients had boost with external beam; 17 (31%) patients had brachytherapy boost; 6 (11%) patients received external beam radiation as Phase I only (without boost), as their tolerance to radiation was poor; and only one (2%) patient had brachytherapy without external beam irradiation (an 80-years-old patient). The mean duration of treatment for all patients with radiation therapy was 5.9 weeks (± 0.86 weeks SD).

Assessment of radiation toxicity was done as per RTOG toxicity criteria^[15] and shown in Table 2.

Table 2. Radiation toxicity profile of the patients in the study.

Toxicity	Grade 0	Grade 1	Grade 2	Grade 3
Proctitis	4 (7.3)	18 (32.7%)	18 (32.7%)	15 (27.3%)
Dermatitis	8 (14.5%)	16 (29.1%)	19 (34.5%)	12 (21.8%)

Nine (16.5%) patients had APR, 9 (16.5%) refused surgery; all of them from the group who received external beam boost; and the rest 37 (67%) patients had low anterior resection (LAR). Pathological response rate after surgical resection is shown in Table 3. After a mean follow up of 22 months, the overall survival was 93% and the disease free survival was 60% (Fig. 1 and 2).

Table 3. Pathological response rate among patients in the study.

Pathological Response	Number	Percentage (%)
CR*	14	25.5
PR†	29	52.7
SD‡	3	5.5
Unknown§	9	16.4

*Complete pathological response

†PR: Partial pathological response

‡SD: Stable disease

§Unknown: Pathological response not known (patients had no surgery after neoadjuvant chemo radiation)

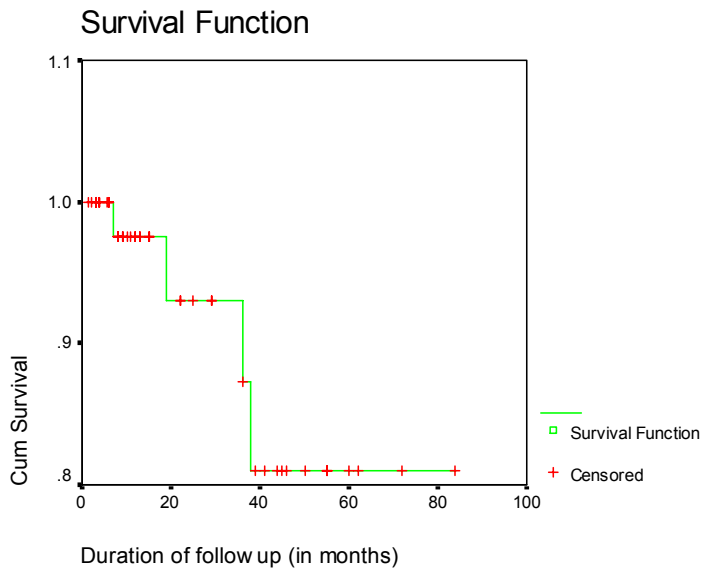


Fig. 1. Overall survival of the study group.

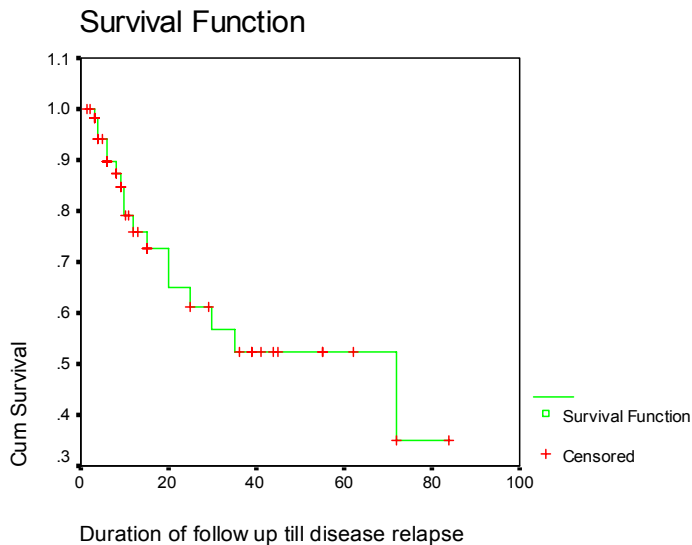


Fig. 2. Disease free survival of the study group.

Comparing different variables with pathological response rate in the univariate analysis, it showed that the only a significant factor is a method of radiation boost; where 8 patients out of 17 who were treated with brachytherapy boost (47%) achieved pathological CR, as compared to only 4 patients out of 22 (18%) who were treated with external beam boost and had surgery (excluding 9 patients who had no surgery); 1 out of 6 patients (16.6%) who were treated without boost and 1 out of 1 treated with brachytherapy alone (100%), a significant rate of pathological CR in favor of the brachytherapy boost group ($p = 0.004$).

Comparing the pathological response rate with other clinical and pathological variables, it showed that there was no correlation between pathological CR and an overall duration of radiation therapy in weeks ($p = 0.17$); T stage ($p = 0.79$), N stage ($p = 0.63$). On multivariate analysis; the only variable that showed statistical significance with pathological response rate was the use of brachytherapy as boost to external beam radiation ($p = 0.02$). There were no correlation between OS ($p = 0.4$) and DFS ($p = 0.5$) and any of the prognostic variables in the study.

Correlation between different modalities of radiation therapy and toxicity profile showed: the use of brachytherapy boost modality had the least incidence of radiation cystitis (no Grade III cystitis) as compared to

3 patients out of 31 (9.6%) in the external beam boost; and the difference was statistically significant ($p = 0.024$). However, the other toxicities were not significantly different among radiation modalities.

Discussion

There is much debate regarding the relative merits and disadvantages of adjuvant versus neoadjuvant combined modality therapy in the treatment of patients with non metastatic rectal carcinoma. Three randomized trials have directly compared the two approaches^[17-19], and in all of them; the overall survival was not different in the two approaches. However, the rate of sphincter preservation and local disease control were higher among the neoadjuvant combined modality approach.

In Phase II, studies of neoadjuvant chemo radiation therapy in locally advanced rectal cancer, the rate of complete pathological response is higher, followed by the preoperative 5-FU-based chemo radiotherapy than the radiation therapy alone^[20-30].

The standard neoadjuvant chemo radiation therapy is based on 5 Fu-Leucovorin concomitant with pelvic irradiation aiming at 50.4 Gy /28 fractions / 5.5 weeks. Many other techniques were developed to compare this standard approach against different radiation therapy protocols. In a Polish randomized trial involving 316 patients with T3-4 rectal cancer^[31] patients; they were randomized between the standard radiation therapy; concomitant 5Fu –Leucovorin arm; and a short course of high dose per fraction of radiation RT (5×5 Gy) followed by surgery. In an early report, the pathological response rate was significantly higher in the chemo radiotherapy group (16% vs. 1%), and there were fewer cases of radial margin positivity (4% vs. 13%). Thus, the rate of sphincter preservation in both groups was comparable (58% vs. 61%, respectively). Toxicity was much higher in the short course high dose per fraction arm. Local failure and survival rates were not reported.

In this study, it was found that patients who received brachytherapy as boost achieved higher rate of CR (47%) as compared to those who received external beam radiation as boost (18%), and the difference was statistically significant ($p = 0.004$). The toxicity profile was in favor of the brachytherapy group with significantly lower incidence of Grade III

radiation cystitis (no patients out of 17) as compared to 3 of 31 (9.6%) patients in external beam boost group; whereas, the incidence of radiation dermatitis and proctitis was not statistically different among the different groups. After a mean follow-up of 22 months, the overall survival was 93%, and the disease free survival was 60%. Using Cox regression analysis method, it showed that the overall survival and disease free survival were not influenced by the modality of radiation therapy used.

There is no rich data about the use of brachytherapy as boost to the external beam radiation therapy in the neoadjuvant setting in rectal cancer in the literature; and the biggest trial about brachytherapy in rectal cancer had been done in Canada by Vuong *et al.* (2005)^[32], where forty-nine patients underwent staging with endoscopic endorectal ultrasound, and the tumor dimensions were determined with MRI of the pelvis. Patients with resectable rectal cancer (staged T2, T3, or early T4) were treated with preoperative high dose rate endorectal brachytherapy concomitant with the standard 5Fu-Leucovorin chemotherapy followed by surgery 6-8 weeks later. The treatment planning was done with the use of a CT simulator; and the treatment was delivered using a flexible endorectal applicator with eight catheters arranged around the circumference of the applicator; and a high dose rate brachytherapy remote after loading system with an Iridium-192 source. Digitally reconstructed radiographs were used as references for daily treatment. A tumor dose of 26 Gy in four fractions was prescribed. Forty-nine patients received planned treatment, and all but 2 patients underwent planned surgery. The pathology specimens showed a complete macroscopic response in 64% of the patients and tumor down-stage in 67% of the patients. This study showed the impact of preoperative brachytherapy on gross tumor control, but not on microscopic remission as in the current study.

In conclusion, the use of brachytherapy boost as part of the neoadjuvant treatment of locally advanced rectal cancer is an attractive modality to be implemented for these patients; for higher pathological complete response rate; acceptable toxicity profile as compared to the external beam boost. These encouraging results need a larger number of patients and thorough research as to have more solid data about the benefit of brachytherapy as boost on the rate of pathological complete response and may perhaps be in OS or DFS.

References

- [1] **Jemal A, Siegel R, Ward E, Murray T, Xu J, Thun MJ.** Cancer statistics, 2007. *CA Cancer J Clin* 2007; **57**(1): 43-66.
- [2] **[No authors listed].** *Cancer Incidence Report*, Saudi Arabia: 2004, Kingdom of Saudi Arabia, Ministry of Health , Saudi Cancer Society, Riyadh , published April 2008; Part II: Overview of Cancer Incidence 2004. pp: 18.
- [3] **Allal AS, Bieri S, Pelloni A, Spataro V, Anchisi S, Ambrosetti P, Sprangers MA, Kurtz JM, Gertsch P.** Sphincter-sparing surgery after preoperative radiotherapy for low rectal cancers: feasibility, oncologic results and quality of life outcomes. *Br J Cancer* 2000; **82**(6): 1131-1137.
- [4] **Rider WD, Palmer JA, Mahoney LJ, Robertson CT.** Preoperative irradiation in operable cancer of the rectum: report of the Toronto trial. *Can J Surg* 1977; **20**(4): 335-338.
- [5] **Gérard A, Buyse M, Nordlinger B, Loygue J, Pène F, Kempf P, Bosset JF, Gignoux M, Arnaud JP, Desai C, et al.** Preoperative radiotherapy as adjuvant treatment in rectal cancer; Final results of a randomized study of the European Organization for Research and Treatment of Cancer (EORTC). *Ann Surg* 1988; **208**(5): 606-614.
- [6] **Wagman R, Minsky BD, Cohen AM, Guillem JG, Paty PP.** Sphincter preservation in rectal cancer with preoperative radiation therapy and coloanal anastomosis: long term follow-up. *Int J Radiat Oncol Biol Phys* 1998; **42**(1): 51-57.
- [7] **Rouanet P, Saint-Aubert B, Lemanski C, Senesse P, Gourgou S, Quenet F, Ycholu M, Kramar A, Dubois J.** Restorative and nonrestorative surgery for low rectal cancer after high-dose radiation: long-term oncologic and functional results. *Dis Colon Rectum* 2002; **45**(3): 305-313.
- [8] **Hyams DM, Mamounas EP, Petrelli N, Rockette H, Jones J, Wieand HS, Deutsch M, Wickerham L, Fisher B, Wolmark N.** A clinical trial to evaluate the worth of preoperative multimodality therapy in patients with operable carcinoma of the rectum: a progress report of National Surgical Breast and Bowel Project Protocol R-03. *Dis Colon Rectum* 1997; **40**(2): 131-139.
- [9] **Kuvshinoff B, Maghfoor I, Miedema B, Bryer M, Westgate S, Wilkes J, Ota D.** Distal margin requirements after preoperative chemoradiotherapy for distal rectal carcinomas: are < or = 1 cm distal margins sufficient? *Ann Surg Oncol* 2001; **8**(2): 163-169.
- [10] **Valentini V, Coco C, Cellini N, Picciocchi A, Genovesi D, Mantini G, Barbaro B, Cogliandolo S, Mattana C, Ambesi-Impiombato F, Tedesco M, Cosimelli M.** Preoperative chemoradiation for extraperitoneal T3 rectal cancer: acute toxicity, tumor response, and sphincter preservation. *Int J Radiat Oncol Biol Phys* 1998; **40**(5): 1067-1075.
- [11] **Francois Y, Nemoz CJ, Baulieux J, Vignal J, Grandjean JP, Partensky C, Souquet JC, Adeleine P, Gerard JP.** Influence of the interval between preoperative radiation therapy and surgery on downstaging and on the rate of sphincter-sparing surgery for rectal cancer: the Lyon R90-01 randomized trial. *J Clin Oncol* 1999; **17**(8): 2396.
- [12] **Grann A, Feng C, Wong D, Saltz L, Paty PP, Guillem JG, Cohen AM, Minsky BD.** Preoperative combined modality therapy for clinically resectable uT3 rectal adenocarcinoma. *Int J Radiat Oncol Biol Phys* 2001; **49**(4): 987-995.
- [13] **Gambacorta MA, Valentini V, Morganti AG, Mantini G, Miccichè F, Ratto C, Di Miceli D, Rotondi F, Alfieri S, Doglietto GB, Vargas JG, De Paoli A, Rossi C, Cellini N.** Chemoradiation with raltitrexed (Tomudex) in preoperative treatment of stage II-III resectable rectal cancer: a phase II study. *Int J Radiat Oncol Biol Phys* 2004; **60**(1): 130-138.

- [14] **Rengan R, Paty P, Wong WD, Guillem J, Weiser M, Temple L, Saltz L, Minsky BD.** Distal cT2N0 rectal cancer: is there an alternative to abdominoperineal resection? *J Clin Oncol* 2005; **23**(22): 4905-4912.
- [15] Radiation Therapy Oncology Group (RTOG): National Cancer Institute; Cancer Therapy Evaluation Program; Common Toxicity Criteria manual June 1, 1999.; version 2 . <<http://www.rtog.org/members/toxicity/ctcmanual.html>>
- [16] **Ryan R, Gibbons D, Hyland JM, Treanor D, White A, Mulcahy HE, O'Donoghue DP, Moriarty M, Fennelly D, Sheahan K.** Pathological response following long-course neoadjuvant chemoradiotherapy for locally advanced rectal cancer. *Histopathology* 2005; **47**(2): 141-146.
- [17] **Roh MS, Colangelo L, Wieand S, O'Connell M, Petrelli N, Smith R, Mamounas E, Hyams D, Wolmark N.** Response to preoperative multimodality therapy predicts survival in patients with carcinoma of the rectum. *J Clin Oncol* 2004; **22**(suppl 145): 246s.
- [18] **Roh MS, Petrelli N, Wieland S, Colangelo L, Smith R, Mamounas E, Hyams D, Wolmark N.** Phase III randomized trial of preoperative versus postoperative multimodality therapy in patients with carcinoma of the rectum: (NSABP R-03). *Proc Am Soc Clin Oncol* 2001; **20**: 123a.
- [19] **Frykholm GJ, Glimelius B, Pahlman L.** Preoperative or postoperative irradiation in adenocarcinoma of the rectum: final treatment results of a randomized trial and evaluation of late secondary effects. *Dis Colon Rectum* 1993; **36**(6): 564-572.
- [20] **Mendenhall WM, Bland KI, Copeland EM 3rd, Summers GE, Pfaff WW, Souba WW, Million RR.** Does preoperative radiation therapy enhance the probability of local control and survival in high-risk distal rectal cancer? *Ann Surg* 1992; **215**(6): 696-706.
- [21] **Myerson RJ, Michalski JM, King ML, Birnbaum E, Fleshman J, Fry R, Kodner I, Lacey D, Lockett MA.** Adjuvant radiation therapy for rectal carcinoma: predictors of outcome. *Int J Radiat Oncol Biol Phys* 1995; **32**(1): 41-50.
- [22] **Chari RS, Tyler DS, Anscher MS, Russell L, Clary BM, Hathorn J, Seigler HF.** Preoperative radiation and chemotherapy in the treatment of adenocarcinoma of the rectum. *Ann Surg* 1995; **221**(6): 778-87.
- [23] **Minsky BD, Cohen AM, Kemeny N, Enker WE, Kelsen DP, Reichman B, Saltz L, Sigurdson ER, Frankel J.** Enhancement of radiation-induced downstaging of rectal cancer by fluorouracil and high-dose leucovorin chemotherapy. *J Clin Oncol* 1992; **10**(1): 79-84.
- [24] **Minsky BD, Cohen AM, Enker WE, Paty P.** Sphincter preservation with preoperative radiation therapy and coloanal anastomosis. *Int J Radiat Oncol Biol Phys* 1995; **31**(3): 553-559.
- [25] **Ngan SY, Burmeister BH, Fisher R, Rischin D, Schache DJ, Kneebone A, MacKay JR, Joseph D, Bell A, Goldstein D.** Early toxicity from preoperative radiotherapy with continuous infusion 5-fluorouracil for resectable adenocarcinoma of the rectum: a Phase II trial for the Trans-Tasman Radiation Oncology Group. *Int J Radiat Oncol Biol Phys* 2001; **50**(4): 883-887.
- [26] **Janjan NA, Crane C, Feig BW, Cleary K, Dubrow R, Curley S, Vauthey JN, Lynch P, Ellis LM, Wolff R, Lenzi R, Abbruzzese J, Pazdur R, Hoff PM, Allen P, Brown T, Skibber J.** Improved overall survival among responders to preoperative chemoradiation for locally advanced rectal cancer. *Am J Clin Oncol* 2001; **24**(2): 107-112
- [27] **Bosset JF, Magnin V, Maingon P, Mantion G, Pelissier EP, Mercier M, Chaillard G, Horiot JC.** Preoperative radiochemotherapy in rectal cancer: long-term results of a phase II trial. *Int J Radiat Oncol Biol Phys* 2000; **46**(2): 323-327.
- [28] **Rich TA, Skibber JM, Ajani JA, Buchholz DJ, Cleary KR, Dubrow RA, Levin B, Lynch PM, Meterissian SH, Rouben LD, et al.** Preoperative infusional chemoradiation therapy for stage T3 rectal cancer. *Int J Radiat Oncol Biol Phys* 1995; **32**(4): 1025-1029.

- [29] **Kim JS, Kim JS, Cho MJ, Song KS, Yoon WH.** Preoperative chemoradiation using oral capecitabine in locally advanced rectal cancer. *Int J Radiat Oncol Biol Phys* 2002; **54**(2): 403-408.
- [30] **Mehta VK, Cho C, Ford JM, Jambalos C, Poen J, Koong A, Lin A, Bastidas JA, Young H, Dunphy EP, Fisher G.** Phase II trial of preoperative 3D conformal radiotherapy, protracted venous infusion 5-fluorouracil, and weekly CPT-11, followed by surgery for ultrasound-staged T3 rectal cancer. *Int J Radiat Oncol Biol Phys* 2003; **55**(1): 132-137.
- [31] **Bujko K, Nowacki MP, Nasierowska-Guttmejer A, Michalski W, Bebenek M, Pudelko M, Kryj M, Oledzki J, Szmeja J, Sluszniaik J, Serkies K, Kladny J, Pamucka M, Kukulowicz P.** Sphincter preservation following preoperative radiotherapy for rectal cancer: report of a randomised trial comparing short-term radiotherapy vs. conventionally fractionated radio chemotherapy. *Radiother Oncol* 2004; **72**(1): 15-24.
- [32] **Vuong T, Devic S, Mofteh B, Evans M, Podgorsak EB.** High-dose-rate endorectal Brachytherapy in the treatment of locally advanced rectal carcinoma: Technical aspects. *Brachytherapy* 2005; **4**(3): 230-235.

تجربة مستشفى جامعة الملك عبد العزيز في علاج سرطان المستقيم بجرعة إضافية بطريقة الأشعة الداخلية

ياسر عبدالعزيز بهادر

قسم الأشعة ، كلية الطب ، جامعة الملك عبدالعزيز

جدة - المملكة العربية السعودية

المستخلص . تقييم الآثار الجانبية واستجابة الورم عندما تستخدم الأشعة الداخلية بجرعة إضافية لعلاج سرطان المستقيم. هذه الدراسة استعدادية لجميع مرضى سرطان المستقيم المعالجين بمستشفى جامعة الملك عبد العزيز. ٥٥ مريضاً تم علاجهم لمدة خمسة أسابيع (٢٥ جلسة) بالأشعة الخارجية، ويتبع ذلك جرعة إضافية عن طريق ثلاث جلسات بالأشعة الخارجية (٣١ مريض)، أو جلستين بالأشعة الداخلية عالية السرعة (١٧ مريض). جميع المرضى أخذوا علاجاً كيميائياً مع الأشعة. معدل الاستجابة، والآثار الجانبية، ومعدل البقاء تمت مقارنتها بين المجموعتين. نسبة الاستجابة الكلية ٢٥.٥٪، والجزئية ٧.٥٢٪، وعدم الاستجابة ٥.١٦٪ الاستجابة الكلية كانت ٤٧٪ في الأشعة الداخلية مقارنة بـ ١٨٪ في الأشعة الخارجية، الآثار الجانبية كانت أقل في مجموعة الأشعة الداخلية. استخدام الأشعة الداخلية عالية السرعة للجرعة الإضافية في علاج سرطان المستقيم أدت إلى نسبة استجابة أعلى، وآثار جانبية أقل، مقارنة مع الأشعة الخارجية.